

# Hybrid cooperative complexes of high and low molecular weight hyaluronans for facial skin rejuvenation in the Oriental mongoloid face: a case series

Elmira Satardinova

Diagnostic Center of the Irkutsk State Medical Academy of Postgraduate Education, Irkutsk, Russia

---

## Abstract

Chrono-aging, i.e. the cutaneous effects of senescence, results in dermal thinning, skin laxity and the formation of wrinkles and fine lines. It correlates with a series of metabolic and histological changes in the skin, notably the marked reduction in hyaluronic acid (HA) production in the extracellular matrix. HA has long been employed as a dermal agent in the field of aesthetic medicine for the correction of soft tissue defects, and IBSA Pharmaceuticals' Profhilo® is the first BDDE-free injectable formulation of stabilized cooperative hybrid HA complexes. Its *in vivo* efficacy and the specifically-developed 5-injection point technique (BAP technique) for the tissue remodeling of the malar and sub-malar areas have been positively evaluated in several independent published studies.

In this case report, Profhilo®'s efficacy for facial skin rejuvenation was tested on 10 individuals (9 females, 1 male) of the Central Eastern European ethnic subpopulation presenting with Oriental mongoloid features. Comparison before and after treatment and between the BAP technique group (5 participants) and diffuse Profhilo® injections group (5 participants) was performed via photographic evidence, Soft Plus and Antera 3D assessment systems.

Although no significant difference in terms of efficacy was identified between the two injection techniques, results revealed a significant amelioration in skin hydration and wrinkle overall size, and a clear, albeit non-significant improvement in skin elasticity, melanin levels and skin texture. Visual comparison also showed a macroscopic improvement in wrinkles, fine lines and skin brightness and tone. Lastly, two patients suffering from pre-existing dermatological conditions reported an amelioration of said complaints after treatment.

## Keywords

Hybrid cooperative complexes, hyaluronic acid, asian mongoloid face, bio aesthetic point, skin laxity

---

Received for publication March 7, 2019; accepted June 4, 2019 - © Salus Internazionale ECM srl - Provider ECM n° 763

## Correspondence

**Elmira Satardinova, MD**

E-mail: [elmira.sat@yandex.ru](mailto:elmira.sat@yandex.ru)

**Introduction**

Chrono-aging is the plethora of metabolic changes occurring in skin physiology as an effect of aging<sup>1</sup>. One well-known manifestation is skin laxity, which is due to both a decrease in collagen and elastin production and to changes in the extracellular matrix including reduction in hyaluronic acid (HA) synthesis<sup>2</sup>.

The glycosaminoglycan HA is widely distributed in epithelial and connective tissues and is a chief component of the extracellular matrix. Here it contributes to tissue hydrodynamics and viscoelasticity, protection from oxidative stress and, most crucially, tissue repair<sup>3-7</sup>. HA's regenerative action is due to its intrinsic anti-inflammatory and bio-stimulating properties, resulting in fibroblast proliferation and increased collagen production<sup>8-10</sup>. The aforementioned properties make HA a highly desirable dermal agent in the field of aesthetic medicine for the correction of soft tissue defects<sup>10</sup>. However, once injected in the dermis, native HA is rapidly degraded by hyaluronidase, making it non-viable for mid- to long-term results<sup>11</sup>. This led to chemically stabilizing HA via cross-linking, a process increasing the molecule's stability, rigidity and elasticity, but whose main drawback is the chemical alteration of HA's natural molecular structure<sup>12</sup>.

This issue was bypassed by Profhilo®, a 2015 product developed by IBSA Pharmaceuticals, whose innovative thermal production process yields stable, cooperative hybrid HA complexes without the need for BDDE or other chemical agents<sup>13</sup>.

The product formulation is a mixture of 32 mg of high molecular weight HA (110-1400 kDa) and 32 mg of low molecular weight HA (80-110 kDa), stabilized by a thermal process consisting of a high-temperature step followed by a low-temperature step. Profhilo®'s unique characteristics include high HA concentration, excellent manageability, low viscosity, optimal tissue diffusion, a low tissue inflammatory response and a duration comparable to weakly cross-linked gel<sup>6,13-15</sup>.

Profhilo®'s effectiveness has been proven in *in vitro* studies, where it demonstrated enhanced tissue repair<sup>6</sup>, extracellular environment remodeling and neofibrogenic and adipogenic properties, while maintaining optimal conditions for fibroblast, keratinocyte and adipocyte vitality<sup>15</sup>. Profhilo®'s clinical indications in the field of aesthetic medicine are in tissue remodeling and improvement of skin laxity of the face, neck and body, and its *in vivo* efficacy has been proven on 120 patients over the course of 4 independent published studies<sup>16-19</sup>. IBSA has furthermore developed the Bio Aesthetic Points (BAP) technique, a Profhilo®-specific injection procedure for the tissue remodeling of the malar and sub-malar areas<sup>16-19</sup>. The technique entails five 0.2 mL bolus injections in the superficial subcutaneous tissue compartment of each hemiface, localized in anatomically receptive facial areas identified for the lack of large vessels and nerve branches<sup>20</sup>: the zygomatic protrusion, the nasal base, the tragus, the chin and the mandibular angles (*Figure 1*). This minimizes the risks and maximizes the diffusion of the product in the lower third of the face.

- 1 **ZYGOMATIC PROTRUSION**  
at least 2 cm away from the external corner of the eye
- 2 **NASAL BASE**
  - draw a line connecting the nostril and tragus
  - draw a perpendicular line starting from the pupil
  - locate the injection point at the intersection of the 2 lines
- 3 **TRAGUS**  
1 cm anterior to the bottom of the tragus
- 4 **CHIN**
  - draw a vertical line in the center of the chin
  - draw a perpendicular line one third from the top of the vertical line
  - from the point of intersection move 1.5 cm towards the oral commissures
- 5 **MANDIBULAR ANGLE**  
1 cm above the mandibular angle

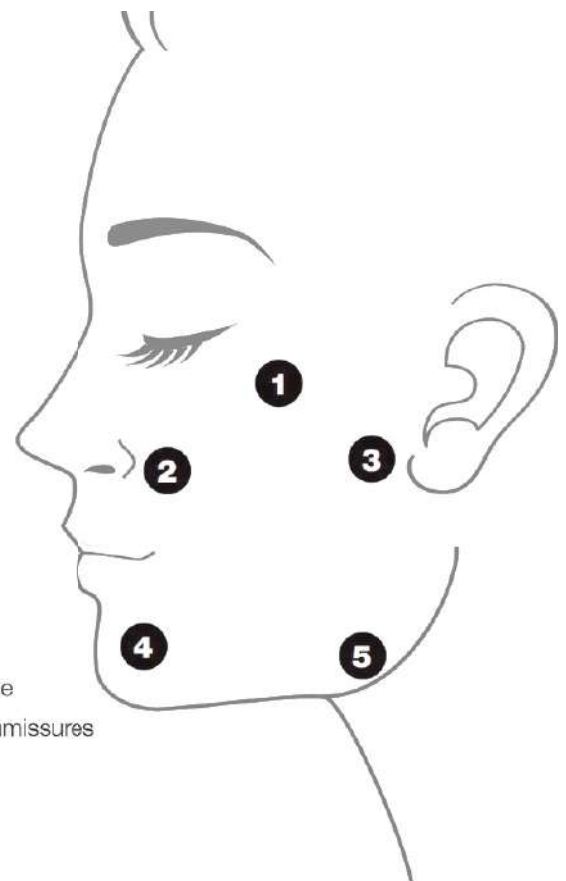


Figure 1 - The BAP (Bio Aesthetic Points) Technique for the treatment of the malar and submalar areas.

The BAP technique allows for highly satisfactory results with only 2 treatments performed 4 weeks apart<sup>21</sup>. Previously published clinical experience on Profhilo®'s efficacy in tissue remodeling prompted the current study, which focuses on an ethnic subpopulation of the Slavs, i.e. the Central Eastern European group. This ethnic group displays so-called Oriental mongoloid face features, which differ from the Caucasian craniofacial form in facial profile, shape of the orbits, cheekbones and mandibular angle. Specifically, the oriental face is wide and round or square, with a flattened facial profile, shorter forehead, and broad nasal bridge with wide nasal wings. The eyes are typically almond-shaped with an elongated intercanthal width, set in fuller upper eyelids with an absent supratarsal fold (so-called "single eyelid"). On the basis of gross histological findings, the single eyelid is due to the fusion of the levator palpebrae aponeurosis with the orbital septum closer to the eyelid margin than in non-Asians, hindering the aponeurotic fibers of the levator from reaching the subcutaneous tissues, which is responsible for the formation of a double eyelid crease<sup>22</sup>. Oriental mongoloid lips are fuller and more protuberant, and the chin more receded than in Caucasian individuals. Overall, the skull morphotype is roughly rectangular, compared to the trapezoidal Caucasian morphotype. Lastly, the mimetic- and chewing muscles are active and well developed: it has been posited that the peculiar Oriental structural features of the zygomatic area and the malaris muscle, which is inconsistent in Caucasian anatomy, prevents soft tissue ptosis, with an overall anti-aging effect of the midface<sup>23,24</sup>.

Despite the numerical strength of the considered population, few studies have assessed facial skin aging in Asian populations. One such study highlighted an increase in transepidermal water loss (TEWL), denoting a loss in stratum corneum barrier function, coupled with a decrease of sebum content, due to a decrease in estrogen-induced sebaceous gland activity<sup>25</sup>.

### Materials and methods

Based on these observations, we investigated the efficacy of Profhilo® for facial skin rejuvenation in 10 individuals (9 females, 1 male) of Oriental appearance aged 26 to 62 (mean = 44 years). We included only participants compliant to the following criteria:

- No rejuvenation procedures performed 6 months ago or later.
- Relatively normal somatic health.
- Not during pregnancy/lactation period.
- No tendency to form cheloid scars.

Participants were requested to maintain the same habits on food, exercise, make-up, cosmetics, and detergent.

A comparative analysis was led between group 1 (5 participants), treated with Profhilo® following the BAP technique for injection points (29G needle) (Figure 1), and group 2 (5 participants), treated with diffuse injections of Profhilo®. The latter technique consisted of diffuse 0.05 mL injections 1 cm<sup>2</sup> apart in the subcutaneous layer of the right and left submalar areas (30G needle). Both groups were treated in two sessions at 4-week intervals, and efficacy was evaluated

pre- and post-treatment. Comparison was performed via photographic evidence, Soft Plus and Antera 3D assessment systems. The Callegari Soft Plus probe system was used to measure skin hydration (in terms of capacity measurement), elasticity (in terms of stress/deformation of the skin by suction application) and melanin (via a double wavelength reflectance photometer) at three points on the right side of the face: the center of the forehead, the outer corner of the eye (1 cm above the zygomatic arch and 2 cm laterally from the outer cantus) and the cheek (2 cm laterally from the labial commissure)<sup>26</sup>.

The Miravex Antera 3D macrophotography camera was employed for 3D topographical and chromophore analysis, specifically assessing overall wrinkle size, skin texture in terms of arithmetical mean roughness and average pigmentation concentration. Again, three areas of the right side of the face were assessed: the glabellar area, the outer corner of the eye and the cheek area near the labial commissure<sup>27</sup>.

Statistical analysis was performed using Fisher's angular transformation ( $\phi$ -method) to compare Group 1 (treated by diffuse injection) and Group 2 (treated by Bio-Esthetic Points). The  $\phi$ -method estimates the statistical significance between the percentages of two samples according to the null hypothesis (H 0): the percent of persons with apparent effect in sample 1 is no more than in sample 2.

### Results

Visual pre- and post-treatment comparisons showed a clear improvement in skin wrinkles and fine lines, with skin appearing brighter and more toned after completion of the procedure (Figure 2).

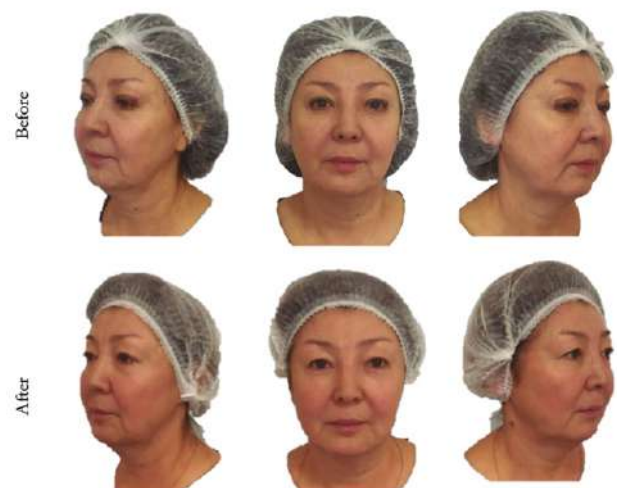

Figure 2 - Sample visual pre- and post-treatment comparison (patient treated with BAP technique).

Visual pre- and post-treatment comparisons showed a clear improvement in skin wrinkles and fine lines with skin subjectively appearing brighter and more toned after completion of the procedure. Though no objective measurements of volumetric changes or sebum changes were performed to support existing research, as this

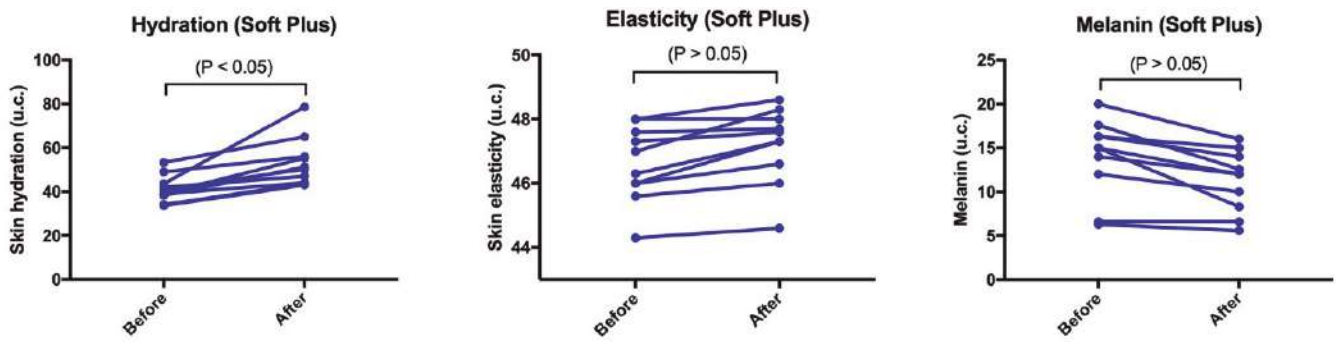


Figure 3 - Soft Plus assessment outputs: paired nonparametric two-tailed T test (Wilcoxon test).

was not within the focus area of this case study. The Soft Plus assessment outputs recorded a significant improvement (P-value 0,008) in skin hydration with an average increase of 12,13 u.c..

Skin elasticity and melanin levels also displayed an overall amelioration of an average 0,59 u.c. and 2,7 u.c. respectively, albeit non-significant (P-value 0,28 and 0,15 respectively) (Figure 3).

Macrophotographical evidence from the Antera 3D camera displays a clear improvement in topographical parameters (Figure 4).

### Wrinkles (Antera 3D)

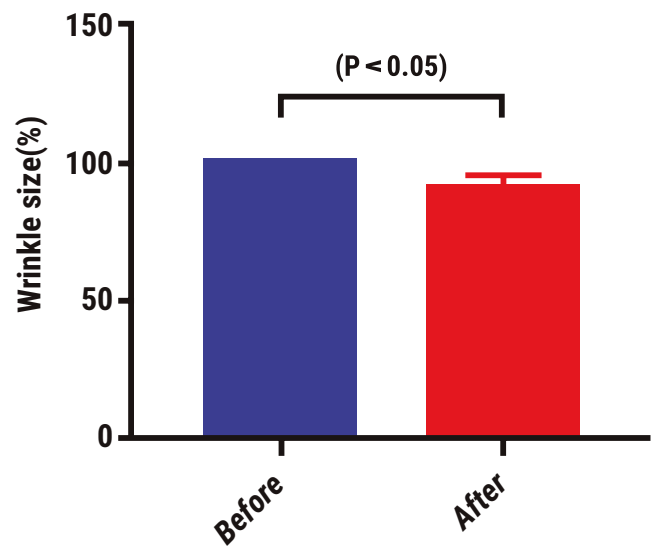


Figure 5 - Antera 3D assessment outputs: paired nonparametric two-tailed T test (Wilcoxon test).

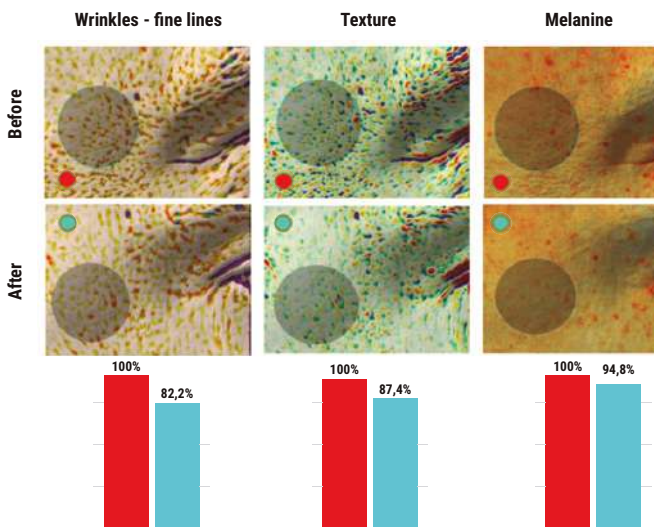


Figure 4 - Sample Antera 3D topographical analysis (patient treated with BAP technique).

Quantitatively, a significant improvement in wrinkle overall size (P-value 0,01) was measured, with an average 8,5% size decrease (Figure 5).

Skin texture was also positively affected, with an average arithmetical mean roughness decrease of 9,2% (P-value 0,002). Lastly, a 4,5% average decrease in skin pigmentation was measured (P-value 0,01).

Furthermore, two patients suffering from pre-existing dermatological conditions reported an improvement in their ailment after treatment.

Patient A (female, 26 years) (Diffuse Injections Group), who suffered from occasional eruptions of acne vulgaris, described a significant decrease in the rash after the second treatment sitting, and an overall reduction in the severity of stagnant post-acne stains.

Patient B (female, 36 years) (BAP Group), suffered from

facial atopic manifestations in wintertime such as skin reddening and peeling. Likewise, after the first treatment sitting the patient noted a significant improvement in her skin condition and claimed complete remission of peeling after the second sitting.

Regarding the injection technique, comparison between group 1, treated following the BAP technique, and group 2, treated with diffuse injections in the subcutaneous layer, revealed no significant difference in terms of efficacy in all the parameter measured.

No adverse events were reported during this study, except for some minor petechiae.

### Discussion

Facial aging is the product of cumulative effects of time on the skin, soft tissues and deep structural components of the face, and is a combined result of skin textural changes and loss of facial volume<sup>1,2</sup>.

Among the skin alterations, loss of tissue elasticity and skin laxity due to decrease in elastin, collagen and hyaluronic acid production strongly affects the phenotypic presentation of the face, causing superficial



textural wrinkling and alterations of its 3D topography. In recent years, there has been a steady increase in nonsurgical procedures for facial rejuvenation<sup>1,2</sup>.

Factors which make the nonsurgical approach so appealing are the immediacy of the cosmetic result and a short recovery time. Profhilo® is an exclusive skin bioremodeling treatment designed by IBSA Pharmaceuticals to treat loss of facial volume and elasticity. Profhilo®'s stabilized hybrid hyaluronic acid complexes stimulate the production of collagen and elastin, thus significantly improving the appearance of wrinkles and fine lines, while increasing tone and hydration across the face. Previous published clinical experience has tested the efficacy and tolerability of Profhilo® on 120 patients in 4 independent studies, with highly satisfactory quantitative results in terms of skin hydration, elasticity, trans-epidermal water loss (TEWL), validated clinical scales (WSRS, FVLS and Beagley and Gibson Scale) and patient and doctor satisfaction rates, with no relevant side effects<sup>17-21</sup>.

Based on Profhilo®'s success in the Caucasian ethnicity, the present report aimed to test the treatment's efficacy on a different ethnic subpopulation, i.e. the Central Eastern European group, which exhibits so-called Asian mongoloid face features. In this case report, 10 patients (9 female, 1 male) were treated with subcutaneous injections of Profhilo® 2,0 ml for facial skin rejuvenation. Photographic pre- and post-treatment comparison revealed a smoothing and lightening of the skin, with macroscopic improvement of wrinkles and fine lines. Quantitative analysis and topographical measurements further highlighted a significant increase in skin hydration and a slight improvement in skin elasticity, confirmed the improvement in skin texture and wrinkle severity, and recorded a decrease in skin pigmentation, probably due to the antioxidant activity of HA<sup>28</sup>. Furthermore, two patients with pre-existing dermatological conditions, namely acne vulgaris and atopic dermatitis, achieved remission after treatment. These results confirm the *in vitro* properties exhibited by Profhilo®: an increase in expression levels of collagen in fibroblasts and keratinocytes and of elastin in the extracellular matrix, combined with enhanced adipogenic differentiation and proliferation of adipose-derived stem cells (ASCs), resulting in excellent regenerative action.

The case report confirms Profhilo® as a unique product with polypotent properties, and as an effective and highly tolerable nonsurgical skin bioremodeling treatment in patients of diverse ethnicities.

#### Acknowledgments

The authors are grateful to Alba Sommerschild for help in writing the manuscript. The medical writing has been supported by IBSA Farmaceutici Italia Srl.

## REFERENCES

- Terranova F. Fisiopatologia dell'idratazione cutanea. *Tecniche Nuove*; 2006.
- Uitto J. The role of elastin and collagen in cutaneous aging: intrinsic aging versus photodamage. *J Drugs Dermatol*. 2008; 7(Suppl):s12-6.
- Prost-Squarcioni C, Fraitaig S, Heller M, Boehm N. Functional histology of dermis. *Ann Dermatol Venereol*. 2008; 135(1 Pt 2):1S5-20.
- Smallwood R. Computational modeling of epithelial tissues. *Wiley Interdiscip Rev Syst Biol Med*. 2009; 1(2):191-201.
- Hiramoto K, Kobayashi H, Yamate Y, Ishii M, Sato EF. Intercellular pathway through hyaluronic acid in UVB-induced inflammation. *Exp Dermatol*. 2012; 21(12):911-4.
- D'Agostino A, Stellavato A, Busico T, et al. In vitro analysis of the effects on wound healing of high- and low-molecular weight chains of hyaluronan and their hybrid H-HA/L-HA complexes. *BMC Cell Biol*. 2015; 16:19.
- Dicker KT, Gurski LA, Pradhan-Bhatt S, Witt RL, Farach-Carson MC, Jia X. Hyaluronan: a simple polysaccharide with diverse biological functions. *Acta Biomater*. 2014; 10(4):1558-70.
- Vigetti D, Karousou E, Viola M, Deleonibus S, De Luca G, Passi A. Hyaluronan: biosynthesis and signaling. *Biochim Biophys Acta*. 2014; 1840(8):2452-9.
- Moreno A, Martinez A, Olmedillas S, Bello S, de Miguel F. Hyaluronic acid effect on adipose-derived stem cells. Biological in vitro evaluation. *Rev Esp Cir Ortop Traumatol*. 2015; 59(4):215-21.
- Stern R, Maibach HI. Hyaluronan in skin: aspects of aging and its pharmacologic modulation. *Clin Dermatol*. 2008; 26(2):106-22.
- Tammi R, Agren UM, Tuhkanen AL, Tammi M. Hyaluronan metabolism in skin. *Prog Histochem Cytochem*. 1994; 29(2):1-81.
- Alessandrini A, Di Bartolo C, Pavesio A, Pressato D. ACP gel: a new hyaluronic acid-based injectable for facial rejuvenation. Preclinical data in a rabbit model. *Plast Reconstr Surg*. 2006; 118(2):341-6.
- Profilo®. Patient Information Leaflet. [https://www.ibsaderma.com/it/profilo\\_system.htm](https://www.ibsaderma.com/it/profilo_system.htm). Accessed December, 2018.
- Sundaram H, et al. Poster Presentation, American Society for Dermatologic Surgery (ASDS) Annual Meeting 2016, November 10-13, New Orleans, LA.
- Stellavato A, Corsuto L, D'Agostino A, et al. Hyaluronan Hybrid Cooperative Complexes as a Novel Frontier for Cellular Bioprocesses Re-Activation. *PLoS One*. 2016; 11(10):e0163510.
- Sparavigna A, Tenconi B. Efficacy and tolerance of an injectable medical device containing stable hybrid cooperative complexes of high and low-molecular-weight hyaluronic acid: a monocentric 16 weeks open-label evaluation. *Clin Cosmet Investig Dermatol*. 2016; 9:297-305.
- Laurino C, Palmieri B, Coacci A. Efficacy, safety, and tolerance of a new injection technique for high- and low-molecular-weight hyaluronic acid hybrid complexes. *Eplasty*. 2015; 15:e46.
- Rodríguez Abascal M, Saldana Fernandez M. Bio-remodelación facial mediante inyección intradérmica de un complejo híbrido estabilizado de ácido hialurónico de alto y bajo peso molecular: estudio prospectivo en 30 pacientes. *Eur Aesth Plast Surg J*. 2015; 5:124-31.
- Beatini A, Schiraldi C, Sparavigna A. Hyaluronic acid hybrid cooperative complexes and the BAP (Bio Aesthetic Points) technique: the new edge in biorejuvenation. *Aesthetic Medicine*. 2016; 2:45-51.
- Pomahac B, Lengele B, Ridgway EB, et al. Vascular considerations in composite midfacial allotransplantation. *Plast Reconstr Surg*. 2010; 125(2):517-22.
- Agolli E et al. Hybrid cooperative complexes of high and low molecular weight hyaluronans (Profilo®): review of the literature and presentation of the VisionHA project. *Esperienze Dermatologiche*. 2018 March; 20(1):5-14.
- Blake CR, Lai WW, Edward DP. Racial and Ethnic Differences in Ocular Anatomy. *International Ophthalmology Clinics*. 2003; 42(3):9-25.
- Zufferey JA. Is the malaris muscle the anti-aging missing link of the midface? *Eur J Plast Surg*. 2013; 36(6): 345-352.
- Coleman SR, Grover R. The anatomy of the aging face: volume loss and changes in 3-dimensional topography. *Aesthet Surg J*. 2006; 26(1S):S4-S9.
- Galzote C, Estanislao R, Suero MO, et al. Characterization of facial skin of various Asian populations through visual and non-invasive instrumental evaluations: influence of age and skincare habits. *Skin Res Technol*. 2013; 19(4):454-465.
- Callegari Soft Plus catalogue. <http://pdf.medicalexpo.it/pdf/callegari/soft-plus/67937-72848.html>. Accessed December, 2018.
- Miravex Antera 3D macrophotography camera catalogue. <http://miravex.com/antera-3d>. Accessed December, 2018.
- Ke C, Sun L, Qiao D, Wang D, Zeng X. Antioxidant activity of low molecular weight hyaluronic acid. *Food Chem Toxicol*. 2011; 49(10):2670-5.