

## ORIGINAL CONTRIBUTION

# Synergic effect of plasma exeresis and non-cross-linked low and high molecular weight hyaluronic acid to improve neck skin laxities

Alessia Paganelli MD  | Victor Desmond Mandel MD | Giovanni Pellacani MD, PhD |  
Elena Rossi MD

Department of Dermatology, University of Modena and Reggio Emilia, Modena, Italy

**Correspondence**

Alessia Paganelli, Department of Dermatology, University of Modena and Reggio Emilia, via del Pozzo 71, 41124 Modena, Italy.  
Email: alessia.paganelli@gmail.com

**Abstract**

**Background:** Many therapeutic options are today available for neck aging, but little evidence exists about the efficacy of combining such procedures. Nonsurgical treatment of neck laxities and wrinkles is often preferred by patients, and combined strategies are nowadays emerging as the standard of care. Both plasma exeresis and hyaluronic acid (HA) injection are two emerging techniques in this setting.

**Aims:** To investigate the synergic effect of plasma exeresis and non-cross-linked HA injection, in stabilized hybrid complex of low and high molecular weight, in terms of both tolerability (assessed using VAS scale of pain) and improvement of neck skin laxities, according to the GAIS score assigned by patients and clinicians.

**Patients/Methods:** Ten consecutive patients with signs of neck skin laxities ( $\geq$  type 3 according to the Glogau wrinkle scale) aged between 35 and 65 years were enrolled in our study. Two treatment sessions were performed. During the first session, both plasma exeresis and HA injection were performed. Patients were re-evaluated after 30 days, and HA injection in the wrinkles of the neck was repeated. After 30 days from the second treatment session, a follow-up visit was performed to assess global efficacy of the two-step combined treatment and to monitor eventual long-term side effects.

**Results:** A GAIS score of 1 or 2 was present in 90% of the treated cases, according to both patients and clinicians. Mean VAS value for pain was 2.4/10. Minor side effects such as erythema and/or edema were transient and completely resolved. No major adverse events were observed.

**Conclusions:** We strongly encourage the combined treatment with plasma exeresis and non-cross-linked HA injection for its promising remodeling effects in the field of neck rejuvenation.

**KEYWORDS**

aesthetic medicine, aging, hyaluronic acid, neck laxities, plasma exeresis, wrinkles

## 1 | INTRODUCTION

Aging of the neck is characterized by several skin changes that include horizontal wrinkling, laxity, prominence of the platysmal bands, loss of the mandibular contour, accumulation of submental fat, and cutaneous dyspigmentation. Nowadays, many therapeutic options are available for the treatment of such conditions.

Various surgical procedures are today proposed for neck rejuvenation and go from liposuction to more complex surgical intervention such as full neck undermining with complete platysma transection and midline platysma approximation or lateral skin-platysma displacement.<sup>1,2</sup> Many cosmetic options exist to address the single signs of neck aging individually, but little literature exists about the safety and efficacy of combining such procedures and devices. Possible therapeutic strategies include the following: intense pulsed light, ablative and nonablative fractional lasers, microfocused ultrasound, radiofrequency, cryolipolysis, deoxycholic acid, neuromodulators, hyaluronic acid (HA) dermal fillers, calcium hydroxyapatite and the so-called "Nefertiti lift," which consists of injecting the platysmal bands and the inferior border of the mandible with botulinum toxin.<sup>3-6</sup> Recently published articles stressed the importance of combining those strategies.<sup>7-9</sup> However, alternative options still have to be explored.

Plasma exeresis is an emerging nonsurgical technique in the field of cosmetic dermatology and aesthetic medicine that sublimates the treated area without damaging the surrounding tissues. Basically, the ionization of gases in the atmosphere of the gap (the space between the tip of the instrument and the tissue to treat) generates the "plasma." The quantity of the plasma produced depends on the air exchange in the ionization space or on the presence in this area of particular gasses (eg, argon). According to the type of skin blemish requiring treatment, two different kinds of techniques can be used (a) continuous mode: for the removal of cutaneous lesions, like seborrheic keratosis or solar lentigos and (b) spot technique: used for the treatment of skin laxities through sublimation of punctiform areas with no overlaps, with spots never lasting more than 2 seconds. It has not only been used in the context of nonsurgical blepharoplasty<sup>10</sup> but also demonstrated effect for treating other aesthetic issues such as acne scars and Favre-Racouchot disease.<sup>11,12</sup>

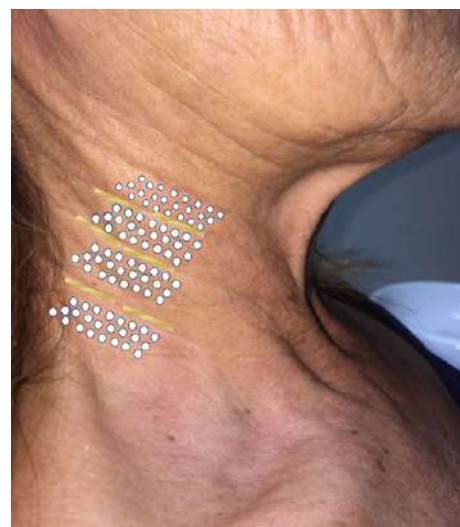Hyaluronic acid injections have not been the mainstay of the treatment for the aging neck, but recently, a few publications have reported their effect on horizontal neck lines.<sup>4,13</sup> PROFHILO® (IBSA) is an ultrapure non-cross-linked HA that promotes a multilevel and dynamic remodeling, leading to an improvement of the extracellular matrix in terms of elasticity and support, promoting and maintaining the viability of fibroblasts, keratinocytes, and adipocytes.<sup>14,15</sup> One of its main indications is the treatment of neck laxities. The aim of our work was to investigate the synergic effect of plasma exeresis and non-cross-linked HA injection, in stabilized hybrid complex of low and high molecular weight, to improve neck skin laxities.

## 2 | MATERIALS AND METHODS

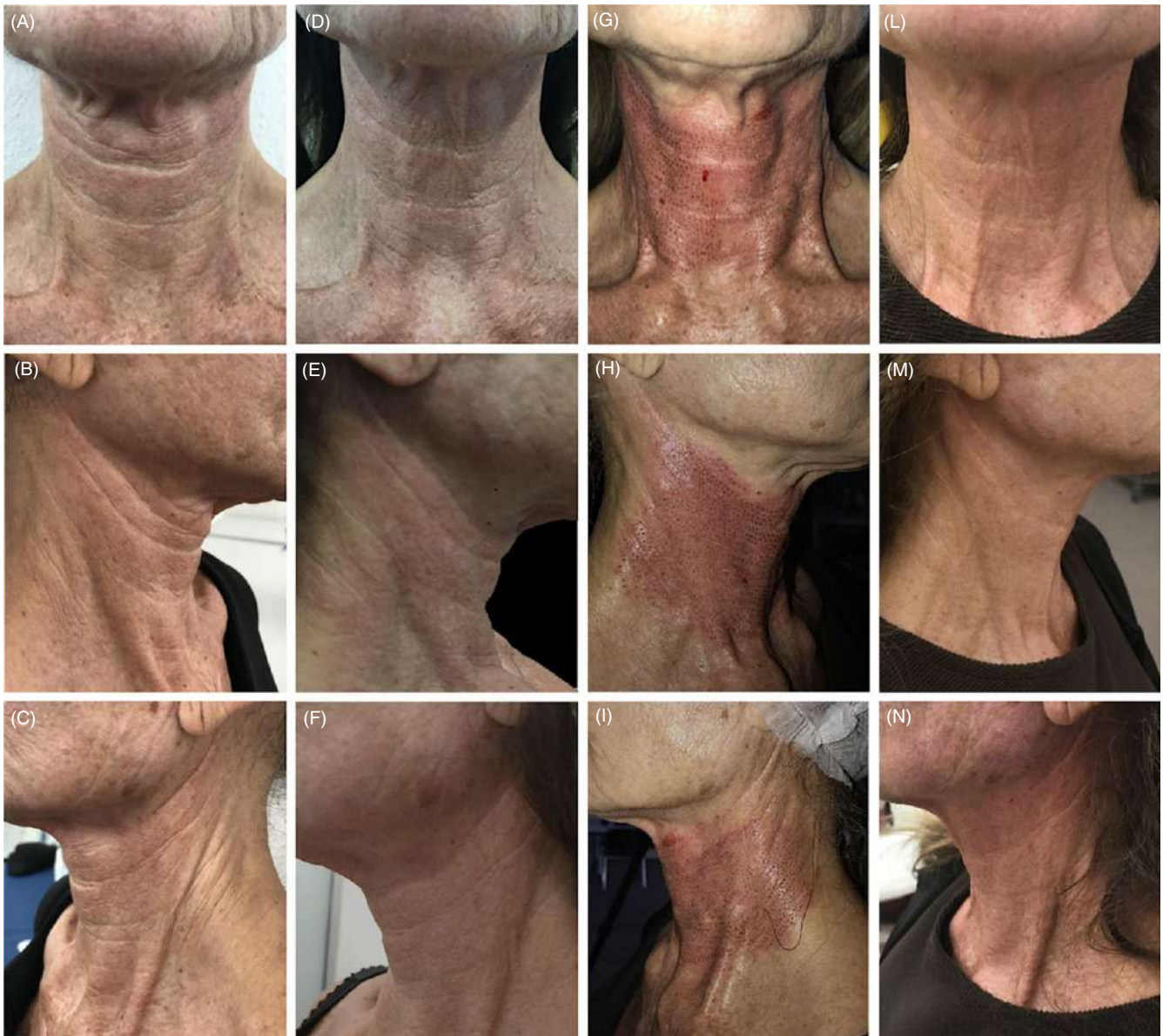We enrolled 10 consecutive patients with an age ranging from 45 to 63 years old (mean 56). All of them were females. Inclusion criteria were the presence of neck skin laxities ( $\geq$  type 3 according to the Glogau wrinkle scale), an age between 35 and 65 years. Pregnant and breastfeeding patients were excluded. Other exclusion criteria were the presence of an active infection, collagenopathies, or other autoimmune connective tissue disorders and the presence of hypertrophic scars in the area to be treated. All the patients signed an informed consent, and the study was conducted in accordance with the principles of Helsinki.

The aim of our work was to investigate the synergic effect of plasma exeresis and non-cross-linked HA injection, in stabilized hybrid complex of low and high molecular weight. The major end points considered were treatment tolerability assessed using Visual Analogic Scale (VAS) of pain and improvement of neck skin laxities, according to the Global Aesthetic Improvement Scale (GAIS) score assigned both by patients and by clinicians.

Two treatment sessions were performed. During the first session (t0), after clinical evaluation, both plasma exeresis and HA injection were performed (Figure 1). At t0, patients were asked to give a score for the pain caused by the treatment according to the visual analogic scale (VAS) for pain. Patients received written indications for post-treatment care: wash the area with neutral soap, disinfect twice a day until scabs spontaneously fall off, and avoid early removal of the scabs and sun exposure for at least 1 month. The application of hypoallergenic fluid foundation was advised. Patients were re-evaluated after 30 days (t1), and HA injection was repeated. After 2 months from t0 (t2), a follow-up visit was performed to assess global efficacy of the two-step combined treatment, patient satisfaction and eventual long-term side effects. At t2, both patients and clinicians were asked to give a score for the clinical improvement according to the



**FIGURE 1** Schematic representation of the combined treatment. White dots: sites of plasma exeresis (spot technique). Yellow lines: sites of hyaluronic acid injection



**FIGURE 2** Clinical pictures of two different patients taken at t0 (panels A-C), t30 (panels D-F), after treatment (panels G-I), and t60 (panels L-N). The improvement both of cutaneous laxity and horizontal wrinkling is evident

GAIS. Photographic images were taken before the procedure, immediately after the treatment and at every subsequent visit (Figure 2). Clinical pictures were collected by using an 8-megapixel iSight camera with 1.5  $\mu\text{m}$  pixels and an f/2.2 aperture. A 6-month follow-up visit ( $\pm 2$  weeks) was performed for all patients included in the study to assess the necessity of repeating the treatment.

In our study, plasma exeresis was performed with Plexr<sup>®</sup> (GMV) applied with the spot technique. Treated tissues “sublimate” without heat transmission to surrounding areas and subcutaneous fat. Particular frequencies and tensions have been studied specifically to obtain a noninvasive and superficial action. Together with the absence of direct contact with the operator and/or with the patient, this makes the instrument safe even when working on sensible and delicate areas, without any thermal damage or electric shock. The mechanism of action limiting the tissue damage makes this technique

lacking absolute contraindications. However, an accurate medical history to assess the absence of exclusion criteria was mandatory before starting the treatment.

We used an ultrapure grade non-cross-linked HA, produced through a patented biofermentation process, of *Streptococcus Zooepidemicus* (PROFHILO<sup>®</sup>; IBSA), and developed with a unique and innovative thermal production process (NAHYCO<sup>®</sup>: Patented Technology). This is a new technology based on hybrid complexes with both high (H, 1100-1400 kDa) and low (L, 80-100 kDa) molecular weight HA at a final concentration of 64 mg (32 mg L-HA + 32 mg H-HA) in a 2-mL prefilled syringe. The cooling down process after injection leads to the creation of thousands hydrogen bonds between long and short chains of HA, thus generating hybrid stabilized complexes. A 2-mL prefilled syringe was used during each treatment session. Thanks to the unique rheological characteristics of the

**TABLE 1** Global Aesthetic Improvement Scale

Global Aesthetic Improvement Scale	N Patient score	N Clinician score
1. Very much improved	4	3
2. Much improved	5	6
3. Improved	1	1
4. No change	0	0
5. Worsened	0	0

Note. In nine out of 10 cases, both patients and clinicians gave a GAIS score of 1 or 2 at t2.

product, tissue remodeling is easily obtained in only two sessions (with a 4-week interval) using all aesthetic injection techniques, in the superficial subcutaneous layer. Previous studies, in fact, demonstrated a significant improvement in skin hydration after only one treatment and in skin elasticity after two treatments.<sup>16</sup>

### 3 | RESULTS

All the patients completed the treatment protocol. Clinical improvement was present in 10/10 cases, with patient satisfaction being even higher than clinician. A GAIS score of 1 or 2 was present in 90% of the treated cases, with only 1 patient scored 3 both according to patient and clinician (Table 1). Horizontal neck wrinkles were nearly completely restored in all the patients, but those with more signs of aging at baseline were more likely to show greater improvement after treatment (Figure 2). The first session had a mean duration of 40 minutes. VAS at t0 (see Figure 3) revealed minimal pain for the patients. Mean VAS value for pain was 2.4/10. The second treatment session took only 10 minutes to be performed.

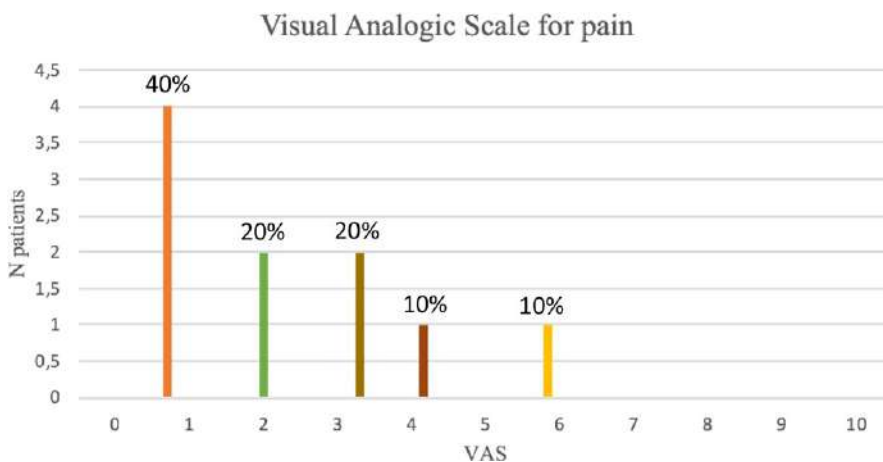
Common adverse effects after HA injection were crust formation, erythema, mild edema, bruises, and/or ecchymoses. All these events were transient and completely resolved. Crusts deriving from the sublimation process lasted from 3 up to 7 days.

Post-treatment crust formation was highly acceptable for patients since it is possible to put immediately fluid foundation on the affected area. As the superficial crusts fell off, the skin surface was slightly erythematous. Cutaneous erythema was transient and lasted for a variable amount of time, from 10 to 30 days. Patients sometimes complained of slight pain without further discomfort. No wound infection, postinflammatory hyperpigmentation, hypopigmentation, or keloid was observed in the treated area. No major adverse events (eg, systemic reactions, anaphylaxis) were observed during both sessions. No long-term side effects were noticed by the patients at t2. Since the treatment with hyaluronic acid can be repeated after 6 months, we did not consider 6-month follow-up results to be a major end point of the study. However, all the patients included in the study had a 6-month follow-up visit and were still satisfied of the results achieved. None of the patients required further treatment and the results were still visible after 6 months (see Figure 4).

### 4 | DISCUSSION

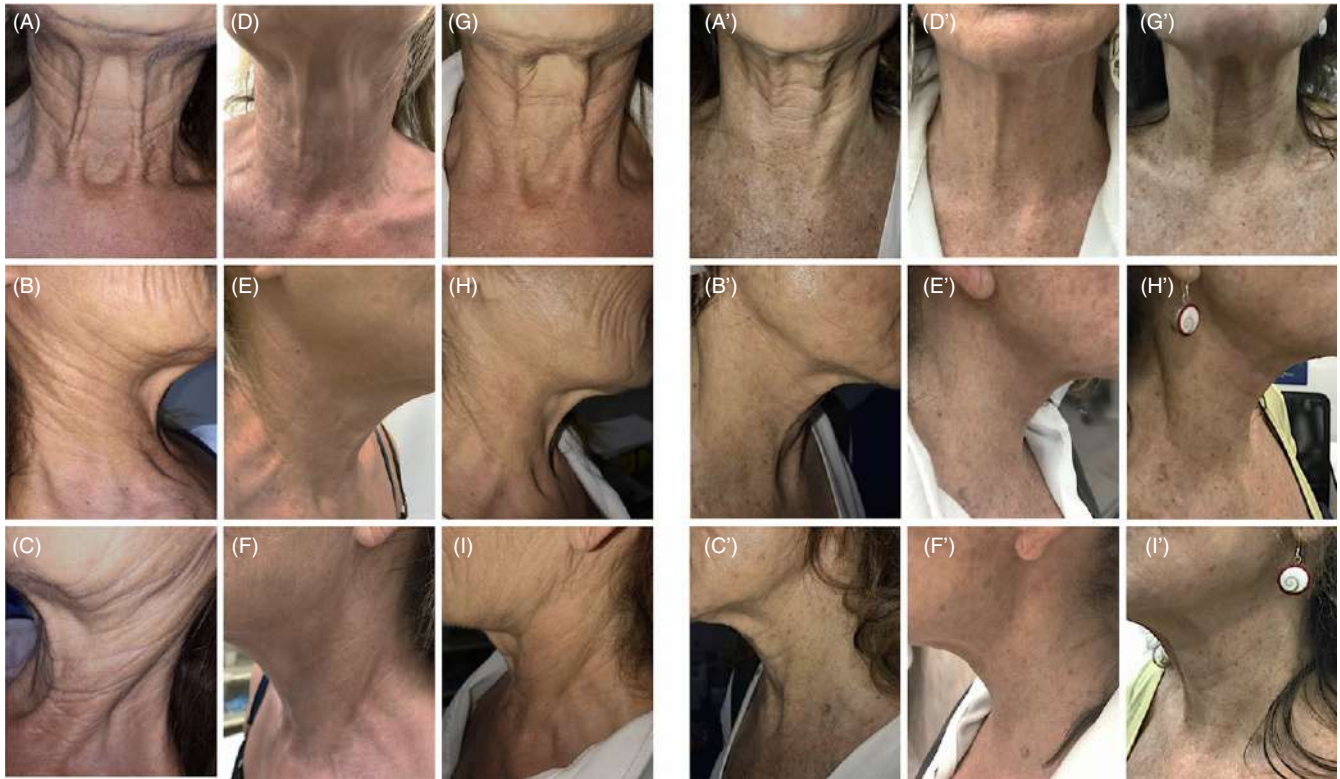Nonsurgical treatment of neck laxities and wrinkles is often preferred by patients due to the noninvasive nature of the treatment and can also be offered to patients at surgical risk. The synergic effect of plasma exeresis and non-cross-linked HA injection provided clinical improvement as documented by the GAIS scores. Both procedures were well tolerated with high subject satisfaction. The study had two main limitations: First, a relatively small number of patients were treated with this particular combined technique; second, gold standard treatments to use as a control are lacking. Moreover, the individual use of hyaluronic acid injection and plasma exeresis has not been systematically investigated in literature with our parameters, so a direct comparison between the combined technique and the single treatments is not feasible.

Plasma exeresis has been used in human aesthetic medicine for perioral wrinkles, eyelid dermatochalasis, and other benign skin conditions. It seems to be a promising, fast and safe, noninvasive



**FIGURE 3** Visual Analogic Scale for pain assessed after the first treatment session (t0). As shown in figure, the combined procedure caused only minimal pain for the patients, with only one patient giving a score higher than<sup>4</sup>





**FIGURE 4** Clinical pictures of two different patients taken at t0 (panels A-C and A'-C'), t60 (D-F and D'-F'), and at 6 mo (G-I and G'-I'). The patients were still satisfied of the results achieved and did not require further treatment at 6 mo.

solution in the field of neck rejuvenation as well. Plasma exeresis is strictly operator dependent: There are no prefixed parameters and the expertise of the physician is of fundamental importance both in the choice of the spot disposition and in the timing of the spot generation. HA injection improved noticeably the results obtained with plasma exeresis. Non-cross-linked HA had the capability of flowing uniformly through entire anatomic units after injection and therefore homogeneously expanding fat compartments in challenging areas where even low viscosity fillers can produce contour irregularities.

Combined strategies are nowadays emerging as the standard of care for patients with neck skin laxities.<sup>17</sup> The combined treatment with plasma exeresis and non-cross-linked HA injection represents an intriguing new paradigm for skin restoration and improvement of neck laxity. We strongly encourage this solution because, in our experience, it demonstrated promising remodeling effects in the field of neck rejuvenation. However, further studies are needed to confirm our data.

#### CONFLICT OF INTEREST

No conflict of interest declared.

#### ORCID

Alessia Paganelli  <https://orcid.org/0000-0002-0916-7769>

#### REFERENCES

1. Pelle-Ceravolo M, Angelini M, Silvi E. Treatment of anterior neck aging without a submental approach: lateral skin-platysma displacement, a new and proven technique for platysma bands and skin laxity. *Plast Reconstr Surg*. 2017;139(2):308-321.
2. Pelle-Ceravolo M, Angelini M, Silvi E. Complete platysma transection in neck rejuvenation: a critical appraisal. *Plast Reconstr Surg*. 2016;138(4):781-791.
3. Wang Y, Wang B, Zhang Q, Ma J. New soft tissue filler derived from autologous keratin and fibroblast for neck wrinkles. *J Cosmet Dermatol*. 2018;17(4):600-605.
4. Lee SK, Kim HS. Correction of horizontal neck lines: our preliminary experience with hyaluronic acid fillers. *J Cosmet Dermatol*. 2018;17(4):590-595.
5. Jabbour SF, Kechichian EG, Awaida CJ, Tomb RR, Nasr MW. Botulinum toxin for neck rejuvenation: assessing efficacy and redefining patient selection. *Plast Reconstr Surg*. 2017;140(1):9e-17e.
6. Yutskovskaya YA, Kogan EA. Improved neocollagenesis and skin mechanical properties after injection of diluted calcium hydroxylapatite in the neck and décolletage: a pilot study. *J Drugs Dermatol*. 2017;16(1):68-74.
7. Jeon H, Kim T, Kim H, Cho SB. Multimodal approach for treating horizontal neck wrinkles using intensity focused ultrasound, cohesive polydensified matrix hyaluronic acid, and incobotulinumtoxin A. *Dermatol Surg*. 2018;44(3):421-431.
8. Doh EJ, Kim J, Lee DH, Park JY. Neck rejuvenation using a multimodal approach in Asians. *J Dermatolog Treat*. 2018;29(4):400-404.
9. Casabona G, Nogueira TD. Microfocused ultrasound in combination with diluted calcium hydroxylapatite for improving skin laxity and the appearance of lines in the neck and décolletage. *J Cosmet Dermatol*. 2018;17(1):66-72.

10. Rossi E, Farnetani F, Trakatelli M, Ciardo S, Pellacani G. Clinical and confocal microscopy study of plasma exeresis for nonsurgical blepharoplasty of the upper eyelid: a pilot study. *Dermatol Surg.* 2018;44(2):283-290.
11. Rossi E, Paganelli A, Mandel VD, Pellacani G. Favre-Racouchot syndrome: report of a case treated by plasma exeresis. *J Eur Acad Dermatol Venereol.* 2018;32(11):e411-e413.
12. Rossi E, Mandel VD, Paganelli A, Farnetani F, Pellacani G. Plasma exeresis for active acne vulgaris: clinical and in vivo microscopic documentation of treatment efficacy by means of reflectance confocal microscopy. *Skin Res Technol.* 2018;24(3):522-524.
13. Han TY, Lee JW, Lee JH, et al. Subdermal minimal surgery with HA as an effective treatment for neck wrinkles. *Dermatol Surg.* 2011;37:1291-1296.
14. Stellavato A, Corsuto L, D'Agostino A, et al. Hyaluronan hybrid cooperative complexes as a novel frontier for cellular bioprocesses re-activation. *PLoS ONE.* 2016;11(10):e0163510.
15. D'Agostino A, Stellavato A, Busico T, et al. In vitro analysis of the effects on wound healing of high- and low-molecular weight chains of hyaluronan and their hybrid H-HA/L-HA complexes. *BMC Cell Biol.* 2015;11(16):19.
16. Laurino C, Palmieri B, Coacci A. Efficacy, safety, and tolerance of a new injection technique for high- and low-molecular-weight hyaluronic acid hybrid complexes. *Eplasty.* 2015;15:e46.
17. Vanaman M, Fabi SG, Cox SE. Neck rejuvenation using a combination approach: our experience and a review of the literature. *Dermatol Surg.* 2016;42(Suppl 2):S94-S100.

**How to cite this article:** Paganelli A, Mandel VD, Pellacani G, Rossi E. Synergic effect of plasma exeresis and non-cross-linked low and high molecular weight hyaluronic acid to improve neck skin laxities. *J Cosmet Dermatol.* 2019;00:1-6. <https://doi.org/10.1111/jocd.12976>